



GLOBAL JOURNAL OF MEDICAL RESEARCH: I  
SURGERIES AND CARDIOVASCULAR SYSTEM  
Volume 22 Issue 2 Version 1.0 Year 2022  
Type: Double Blind Peer Reviewed International Research Journal  
Publisher: Global Journals  
Online ISSN: 2249-4618 & Print ISSN: 0975-5888

# Laparoscopic Superselective Transperitoneal Lumbar Sympathectomy for Treating Plantar Hyperhidrosis Lumbar Sympathectomy for or Treating Plantar Hyperhidrosis

By Rodrigo Cadore Mafaldo, Leila Beltrami Moreira, Ozorio Sampaio Menezes, Honório Sampaio Menezes, Danuza Dias Alves, Gustavo RassierIsolan & Gabriella Andressa Marchesin de Castro

**Abstract- Background:** Retroperitoneoscopic lumbar sympathectomy is the standard surgical treatment for plantar hyperhidrosis. However, it is rarely performed due to the technical complexity of the procedure. This study aimed to describe a modified video-assisted lumbar sympathectomy technique, the superselective transperitoneal lumbar sympathectomy.

**Methods:** This is a retrospective study of 32 sympathectomies (16 patients) for plantar hyperhidrosis. The procedure is performed with the patient in the supine position and under general anesthesia. A video camera is introduced through the umbilical trocar, and the dissection forceps are introduced through trocars in the suprapubic area and right-and left-iliac fossa. The patient is placed in the Trendelenburg position at the level of the L3 vertebral body.

**Keywords:** hyperhidrosis, excessive plantar sweating, lumbar sympathectomy, laparoscopic surgery.

**GJMR-I Classification:** DDC Code: 618.92853059 LCC Code: RJ496.E6



Strictly as per the compliance and regulations of:



© 2022. Rodrigo Cadore Mafaldo, Leila Beltrami Moreira, Ozorio Sampaio Menezes, Honório Sampaio Menezes, Danuza Dias Alves, Gustavo RassierIsolan & Gabriella Andressa Marchesin de Castro This research/review article is distributed under the terms of the Attribution-NonCommercial-NoDerivatives 4.0 International (CC BY-NC-ND 4.0). You must give appropriate credit to authors and reference this article if parts of the article are reproduced in any manner. Applicable licensing terms are at <https://creativecommons.org/licenses/by-nc-nd/4.0/>.

# Laparoscopic Superselective Transperitoneal Lumbar Sympathectomy for Treating Plantar Hyperhidrosis

Rodrigo Cadore Mafaldo <sup>α</sup>, Leila Beltrami Moreira <sup>σ</sup>, Ozorio Sampaio Menezes <sup>ρ</sup>,  
Honório Sampaio Menezes <sup>ω</sup>, Danuza Dias Alves <sup>¥</sup>, Gustavo RassierIsolan <sup>§</sup>  
& Gabriella Andressa Marchesin de Castro <sup>x</sup>

**Abstract- Background:** Retroperitoneoscopic lumbar sympathectomy is the standard surgical treatment for plantar hyperhidrosis. However, it is rarely performed due to the technical complexity of the procedure. This study aimed to describe a modified video-assisted lumbar sympathectomy technique, the superselective transperitoneal lumbar sympathectomy.

**Methods:** This is a retrospective study of 32 sympathectomies (16 patients) for plantar hyperhidrosis. The procedure is performed with the patient in the supine position and under general anesthesia. A video camera is introduced through the umbilical trocar, and the dissection forceps are introduced through trocars in the suprapubic area and right-and left-iliac fossa. The patient is placed in the Trendelenburg position at the level of the L3 vertebral body. Under the direct view of the endoscope and with the aid of dissection forceps, a small opening of the posterior peritoneum is made, through which the right and left sympathetic plexuses are reached for sectioning.

**Results:** The cases of 16 patients were analyzed. Most of them were women (n = 12), had a higher education degree, and aged from 19 to 36 years (mean of 28.3 ± 4.5 years). Before the procedure, women reported wearing two or three different pairs of socks per day (mean 2.8 ± 1.1), while men, one or two (mean 1.6 ± 0.5; p = 0.039). 75 % of patients declared being very or extremely satisfied and no association between the level of satisfaction and the number of socks changed before the treatment was made (p = 0.78). Most patients had compensatory hyperhidrosis and no other adverse events.

**Conclusion:** The modified lumbar sympathectomy technique proved to be safe and effective.

**Keywords:** hyperhidrosis, excessive plantar sweating, lumbar sympathectomy, laparoscopic surgery.

**Corresponding Author α:** Rua Doutor Guimarães Rosa, 155 - Boa Vista, Porto Alegre – Rio Grande do Sul/RS – Brasil.

e-mail: nucleodepesquisa@clinicaleger.com.br

**Author σ ω §:** Physician, PhD, SCd.

**Author ρ:** Physician, Specialist.

**Author ¥:** Physician.

**Author x:** Biomedical.

## I. INTRODUCTION

Plantar hyperhidrosis is characterized by excessive sweating of the feet mediated by sympathetic stimulation. In severe cases, patients may have gait disturbances, skin lesions, and cold feet. The prevalence of plantar hyperhidrosis is estimated to be from 2.9%<sup>1</sup> to 9%<sup>2</sup>. Retroperitoneoscopic lumbar sympathectomy is the standard surgical treatment. This procedure has been performed with a low rate of complications<sup>3-5</sup> and has improved the quality of life of patients affected by plantar hyperhidrosis<sup>6</sup>. However, the surgery requires that the patient be in a semi-lateral position with elevation of the flank and the use of intra-abdominal and retroperitoneal pneumoperitoneum<sup>3</sup>, in addition to, sometimes, being performed in two stages. Some authors perform bilateral sympathectomy which uses a single-sided access and lasts just over an hour<sup>7</sup>. Compensatory hyperhidrosis is the most frequent adverse event and, although infrequent, sexual dysfunction may also occur<sup>8,9</sup>.

This study aims to describe a modified video-assisted lumbar sympathectomy technique, called superselective transperitoneal lumbar sympathectomy, which allows the performance of the procedure using a single access with an easy abdominal approach.

## II. MATERIALS AND METHODS

This is a retrospective study of 32 sympathectomies performed in 16 patients with plantar hyperhidrosis treated by laparoscopic superselective transperitoneal lumbar sympathectomy.

## III. TECHNICAL DESCRIPTION

For better anatomical orientation, considering that the surgery is performed with the patient in the supine position, a simple preoperative abdominal x-ray is performed. The x-ray imaging is done with the patient in the supine position and with the umbilicus marked with a metallic disk, which can be a coin. Thus, the location of the L4 vertebral body can be confirmed in a

straight direction from the umbilicus. The anatomy must be confirmed because there may be anatomical variations or umbilical deviation due to previous abdominal surgery.

The surgery is performed under general anesthesia with the patient in the supine position. A thermometer is placed on each plantar foot surface of the patient. Before anesthetic induction, the temperature of the feet is approximately 25 °C, while after anesthesia, it rises to 32 °C on average.

Pneumoperitoneum with carbon dioxide and pressure of 12 mm of mercury is established and four 5-mm trocars are inserted. The video camera is introduced through the first one placed in the umbilicus. The dissection forceps are introduced through the suprapubic area and right-and left-iliac fossa trocars (Figure 3). The patient is placed in the Trendelenburg position, exposing the root of the mesentery, which is at the level of the L3 vertebral body.

Under the direct view of the endoscope and with the aid of dissection forceps, a small opening of the posterior peritoneum is made close to the third portion of the duodenum after cranial mobilization of the mesentery and intestines (Figure 4).

With the forceps inserted through the umbilical trocar, a lumbar spine projection is made to identify the L3-L4 vertebrae using a C-arm radioscapy to help locate the level of the vertebrae. Thus, consequently, locating the sympathetic chain, which allows for the approach to the sympathetic plexuses on the right and left sides.

Subsequently, the vena cava is bluntly dissected and medially displaced so that the sympathetic chain, usually found behind the vein, can be visualized. The level of the sympathetic resection is confirmed with intraoperative radioscapy at L3-L4 on the right. Thus, the section of the sympathetic chain is carried out.

Similarly, the para-aortic lymph nodes are dissected in order that the right sympathetic chain is reached (Figure 7 and 8). Under intraoperative radioscapy, the right sympathetic chain is sectioned after its level is confirmed at L3-L4. The opening that gives access to the retroperitoneum, which is soon after closed, can be seen in Figure 9.

When the sympathetic section is performed, there is an increase of approximately 2 °C in temperature and significant vasodilation of the lower limbs. Thus, the section of the sympathetic chain can be confirmed.

The surgery lasts approximately one hour and does not require a hospital stay longer than 24 hours. Prophylactic antibiotics are used in surgery and common analgesics are given to the patient postoperatively. After the removal of the stitches, which usually takes 10 days, the patient can resume normal activities. Figure 10 shows the excellent aesthetic result achieved after the procedure.

## IV. RESULTS

The cases of 16 patients who underwent laparoscopic superselective transperitoneal lumbar sympathectomy were analyzed. Most of them were women (n=12) and had a higher education degree. Ages ranged from 19 to 36 years, with a mean of 28.3±4.5 years. Three women had already undergone surgical treatment of plantar hyperhidrosis. Before the procedure, patients mentioned wearing from one to four pairs of socks per day. Women reported wearing two or three different pairs (mean 2.8±1.1), while men, one or two (mean 1.6±0.5; p = 0.039).

Fifty patients were treated over 18 years; however, only 16 were contacted. These underwent the procedure from 1 to 15 years ago. In a telephone interview, 15 patients reported improvement in both feet, while 1 patient described seeing improvement in only one foot and undergoing a second surgery. Patient satisfaction with the treatment was assessed using a five-point Likert scale in which 1 would be dissatisfied; 2, somewhat satisfied; 3, satisfied; 4, very satisfied; and 5, extremely satisfied. Two patients reported being somewhat satisfied (2 points); two were satisfied (3 points); and the other 14 were very or extremely satisfied (4 and 5 points). Among both men and women, 75% of patients declared being very or extremely satisfied. There was no association between the degree of satisfaction and the number of pairs of socks changed before treatment (p=0.78).

Three patients reported improvement in sweating, in addition to the feet, in another region of the body. Most patients (n=13) developed compensatory sweating with the most affected region being the trunk, but with less intense sweating. There were no surgical complications in the case series reported in this study; however, one case required reintervention because the first procedure failed to control the symptoms on one side.

## V. DISCUSSION

This study presented cases of plantar hyperhidrosis treated with the laparoscopic superselective transperitoneal lumbar sympathectomy technique and the vast majority of patients were satisfied with the treatment.

The extraperitoneal lumbar sympathectomy is a technique little used because of the difficulty of its performance and the lack of trained surgeons. Despite the clear improvement in the quality of life of treated patients<sup>6</sup>, the number of patients with the pathology who have delayed surgical treatment is still difficult to assess. As it is performed with a commonly used positioning, the technique described allows for accessing the retroperitoneal space through anterior approaches to the spine, thus, facilitating the procedure.

For having anatomical support, this procedure can be safe pre-and trans-operatively, achieving high levels of satisfaction among patients, as reported after a retroperitoneoscopic lumbar sympathectomy<sup>9</sup>. In this study, there was one unsuccessful case due to the difficulty of dissecting the right-sided nerve; however, during a second intervention, the right lumbar sympathetic chain was sectioned without complications. Compensatory hyperhidrosis was the adverse effect observed in most patients submitted to laparoscopic superselective transperitoneal lumbar sympathectomy. Nonetheless, as it was less intense, it did not negatively affect satisfaction with the surgery. Several studies report that, despite compensatory sweating, the overall quality of life of these patients improves<sup>5,6,10</sup>. No cases of retrograde ejaculation, hemorrhage, visceral injury, infection, or death were recorded.

Compensatory hyperhidrosis occurs in up to two-thirds of cases according to the literature<sup>9-11</sup> and can be exacerbated by the use of a surgical clip to interrupt the sympathetic chain. In these cases, the performance of a new procedure is recommended to remove the clip and section the sympathetic chain<sup>12</sup>. Reinnervation, although less frequent than after thoracic sympathectomy<sup>12</sup>, may also occur and require a new surgical intervention.

The body anatomy in the supine position, the insertion of trocars, and camera positioning are well known by surgeons, making this approach advantageous. Moreover, the location of the lumbar sympathetic chain is anatomically constant and, in rare cases, it is not anatomically favorable. Extraperitoneal lumbar sympathectomy, on the other hand, is a technique that has a longer learning curve as it is not the most common route used by surgeons. Furthermore, it requires longer anesthetic time, as well as greater preparation of the team as a whole for the positioning of the patient<sup>4,7</sup>. For being performed with the patient in a commonly used position, the technique described in this study allows for access to the retroperitoneal cavity through an anterior approach to the spine.

The main limitations of this study were the small number of cases, the difficulty in locating all patients, and the long time elapsed between the surgery and telephone interview in some cases. In contrast, this investigation provides data on long-term evolution cases. There seems to have been no preferential selection of women since the number of women is also higher in several other studies in the literature<sup>5,10,13,14</sup>.

## VI. CONCLUSION

The treatment of plantar hyperhidrosis using the laparoscopic superselective transperitoneal lumbar sympathectomy technique proved to be effective and safe. In addition to sympathectomy, this direct approach to the retroperitoneum could also be used in difficult-to-

access laparoscopic oncologic resections and treat anterior lumbar spine pathologies. Using a robot for this surgical approach is a possibility.

### Conflicts of Interest and Source of Funding

The authors declare that there is no conflict of interest or funding sources.

### Author contributions

- Elaboration and development of the technique  
Rodrigo Cadore Mafaldo  
Ozorio Sampaio Menezes  
Honório Sampaio Menezes
- Project construction and development  
Rodrigo Cadore Mafaldo  
Leila Beltrami Moreira  
Danuza Dias Alves  
Gustavo RassierIsolan
- Construction and development of the article  
Rodrigo Cadore Mafaldo  
Gabriella Andressa Marchesin de Castro
- Editing and article submission  
Rodrigo Cadore Mafaldo  
Ozorio Sampaio Menezes  
Gabriella Andressa Marchesin de Castro

## REFERENCES RÉFÉRENCES REFERENCIAS

1. Strutton DR., Kowalski JW., Glaser DA., et al. US prevalence of hyperhidrosis and impact on individuals with axillary hyperhidrosis: results from a national survey. *J AmAcadDermatol*, 2004; 51(2):241-8. Doi: 10.1016/j.jaad.2003.12.040.
2. Hasimoto EN, Caetano D, Reis TA, et al. Hyperhidrosis: prevalence and impact on quality of life. *J. Bras. Pneumol*, 2018; 44(4): 292-298. Doi: 10.1590/s1806-37562017000000379.
3. Rieger R, Pedevilla S, Pochlauer S. Endoscopiclumbar sympathectomy for plantar hyperhidrosis. *Br J Surg*. 2009.
4. Branco AW., Branco Filho AJ., Kondo W., et al. Bilateral retroperitoneoscopic lumbar sympathectomy by unilateral access. *Braz J UrolInt*, 2011; 27; 37(2): 292-293. Doi: 10.1590/S1677-55382011000200032.
5. Lima SO, Santana VR, Valido DP, et al. Retroperitoneoscopic lumbar sympathectomy for plantar hyperhidrosis. *Jor of Vas Surg*, 2017; 66(6):1806-1813. Doi: 10.1016/j.jvs.2017.05.126.
6. Rieger R., Pedevilla S., Lausecker J. Quality of life after endoscopic lumbar sympathectomy for primary plantar hyperhidrosis. *World J Surg*, 2015 Apr; 39(4).
7. Loureiro M., Lemos Junior AN., Salvalaggio PRO., et al. Minilaparoscopiclumbar sympathectomy with 3 mm instruments for plantar hyperhidrosis, *Jornal Vascular Brasileiro*, 2020; 27; 19:e20190072. Doi: 10.1590/1677-5449.180072.



8. Goldstein M., Ectors P., Dereume JP., et al. Complications of lumbar sympathectomy. Retrospective study of 791 patients ActaChirurgicaBelgica, 1977; 76(1): 73-79.
9. Rieger R. Video-assisted retroperitoneoscopic lumbar sympathectomy. EurSurg 2012; 1:11-13.
10. Loureiro MP, Campos JRM, Kauffman P, et al. Endoscopic lumbar sympathectomy for women: Effect on compensatory sweat. Clinics, 2008; 63(2): 189-196. Doi: 10.1590/S1807-59322008000200006.
11. Thomas I, Brown J, Vafaied J, Schwrtz RA. Palmoplantar hyperhidrosis: A therapeutic challenge. Am Fam Physitian 2004; 69:1117-20.
12. Lyra RM, Campos JRM, Kang DWW, et al. Diretrizes para a prevenção, diagnóstico e tratamento da hiperidrose compensatória. J. bras.Pneumol., 2008; 34(11): 967-977. Doi: 10.1590/S1806-37132008001100013.
13. Campos JRM, Kauffman P, Werebe EC, et al. Quality os life, before and after thoracic sympathectomy: Report on 378 operated patients. Ann ThoracSurg 2003; 76: 886-91.
14. Rieger R, Loureiro MP, Pedevilla S, Oliveira RA. Endoscopic lumbar simpathectomy following thoracic sympathectomy in patients wuith palmoplantar hyperhidrosis. World J Surg 2011; 35: 49-53. Doi: 10.1007/s00268-010-0801-0.

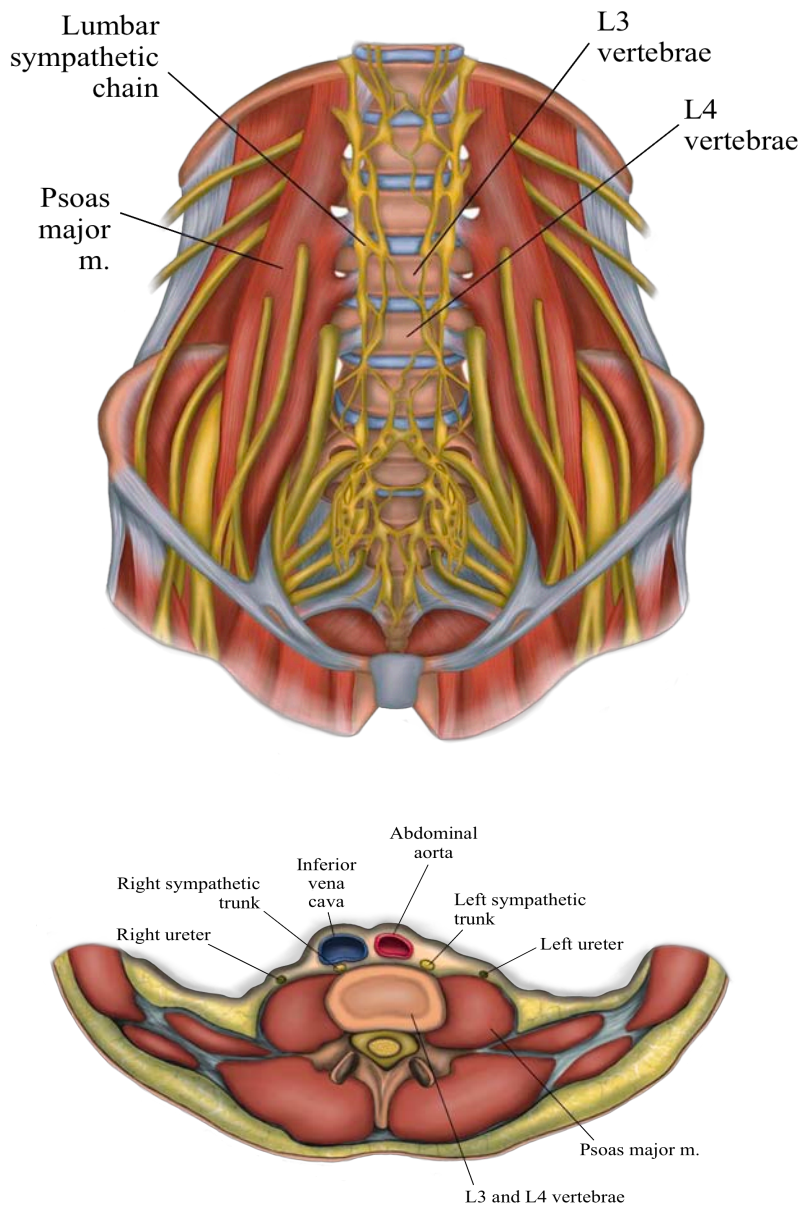
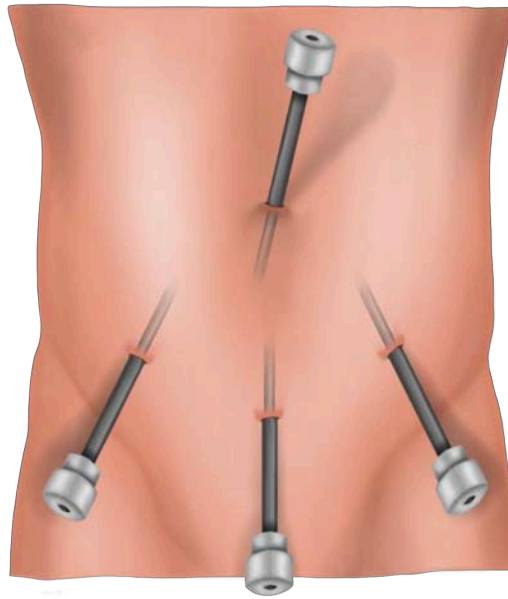
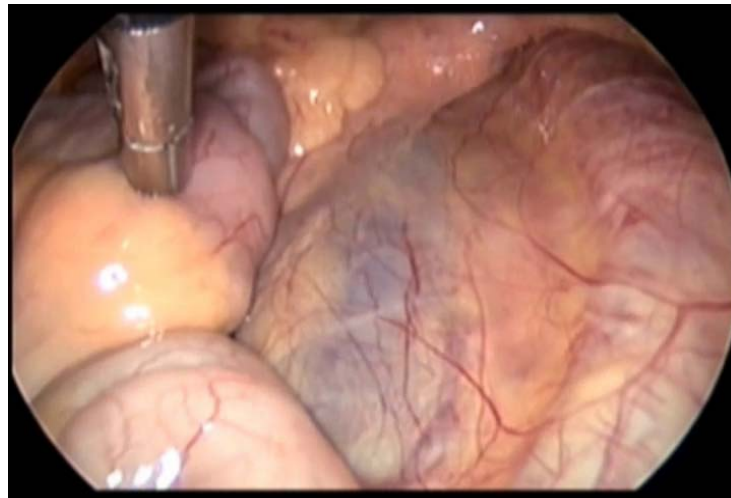


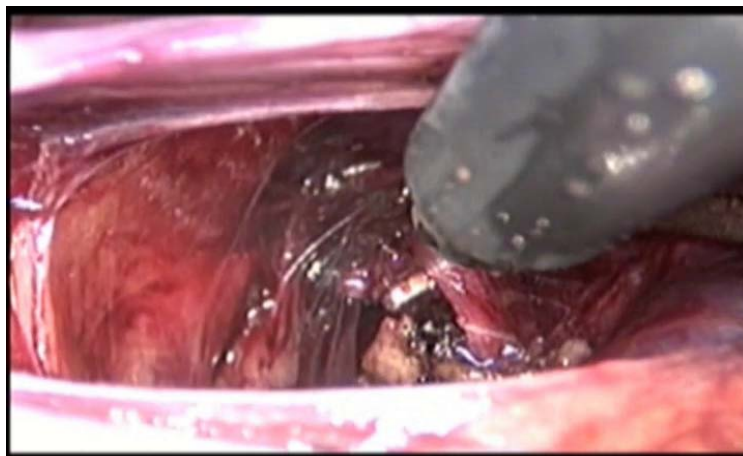
Figure 1 and 2: The anatomy of L4. Source: Own figure.



*Figure 3:* Trocars placed in the umbilicus, suprapubic area, and right-and left-iliac fossa. Source: Own figure.



*Figure 4:* View from left to right, vena cava and aorta artery located retroperitoneally. Source: Own file.



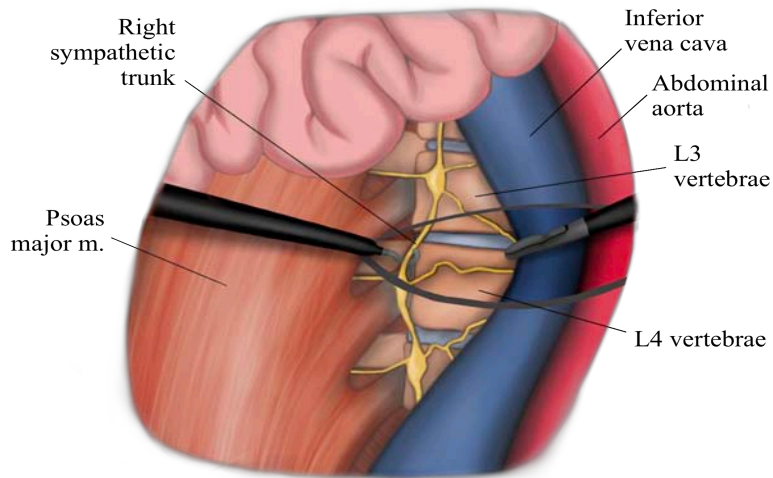


Figure 5 and 6: Opening of the retroperitoneum and dissection lateral to the vena cava. Vena cava is displaced to the right by dissection forceps and the sympathetic chain is visualized in hook forceps. Source: Own figure.

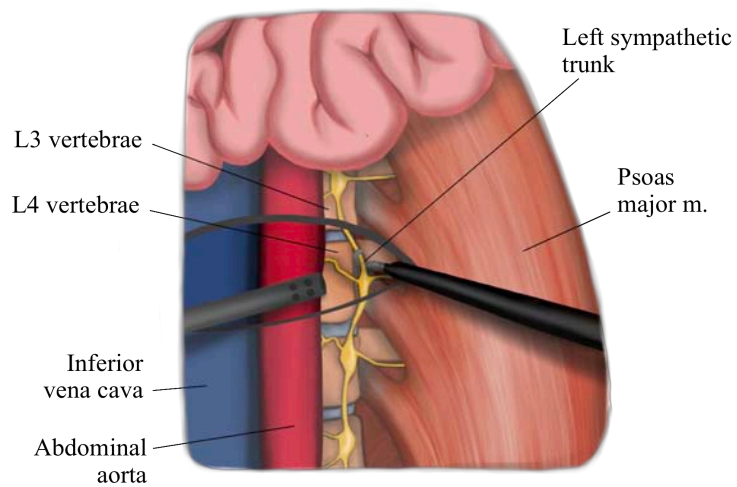
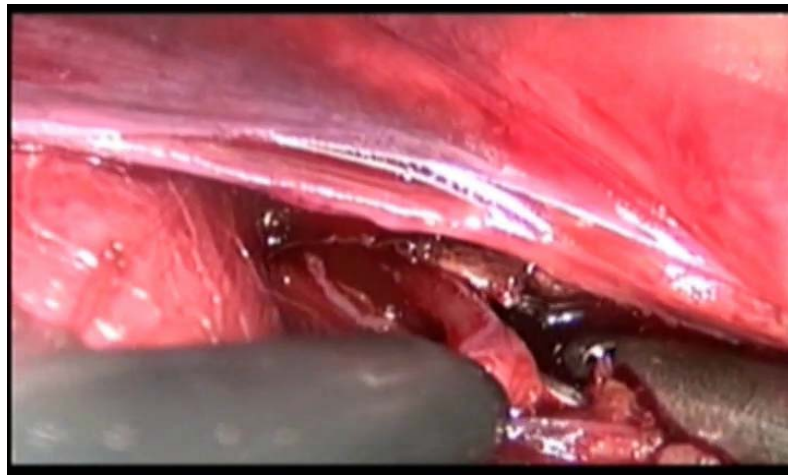


Figure 7 and 8: Left retroperitoneal cavity, aorta displaced to the left, right sympathetic chain dissected in hook forceps. Source: Own figure.

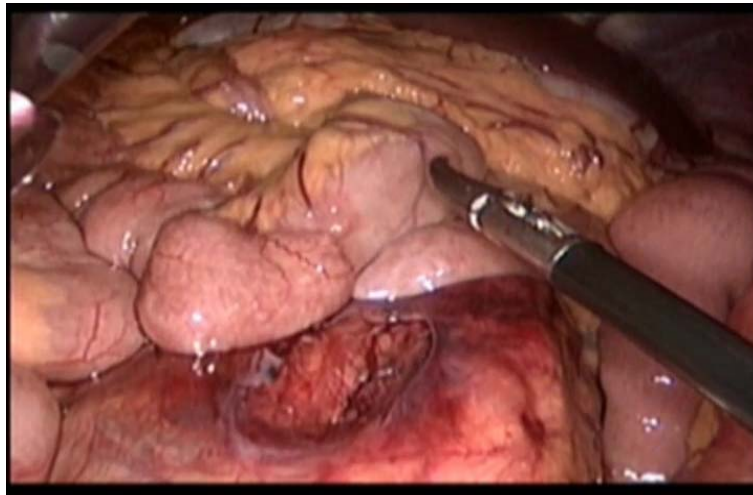


Figure 9: Laparoscopic retro-and transperitoneal opening. Source: Own figure.

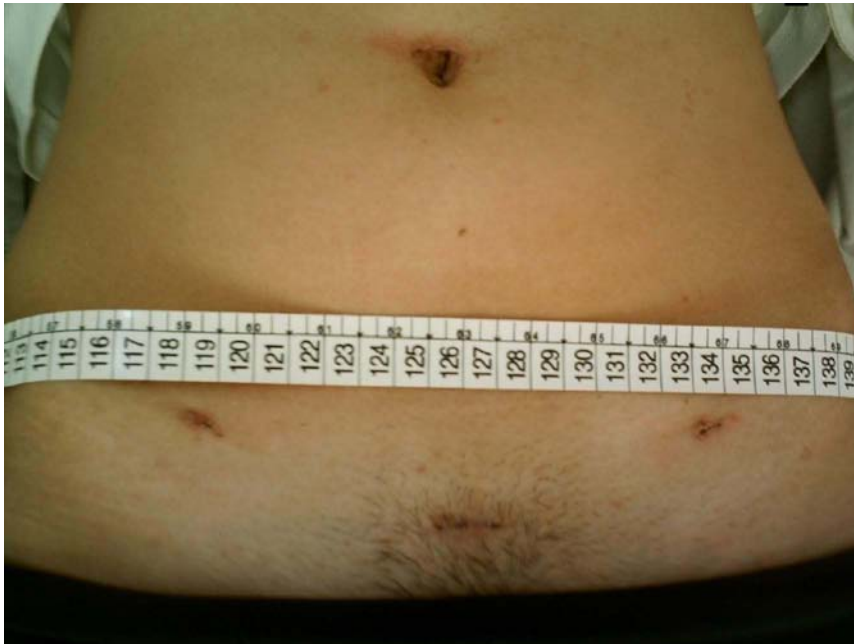


Figure 10: Postoperative of laparoscopic superselective transperitoneal sympathectomy. Source: Own figure.

